AVAILABLE AUTOMATED TOOL FOR MRI IMAGES

HIPPOCAMPAL VOLUME

a) ADABOOST

URL: https://neugrid4you.eu/group/science-gateway/adaboost

How it works: AdaBoost is an automated machine-learning hippocampal segmentation algorithm processing 3D T1-weighted structural brain Magnetic Resonance (MR) scans. Adaboost segments the hippocampus according to the Harp protocol. Once the MRI is uploaded in neuGRID, AdaBoost computes thousands of features of the hippocampus region providing in 45 minutes a .pdf report (fig.1a). The normative dataset is composed by 200 controls. This has been made possible thanks to the support of the following contributors: Paul Thompson (USC) and FP7 EU DECIDE initiative.
Reference: Morra et al, NeuroImage 2008;43(1):59–68

Figure 1a: Example of AdaBoost report.

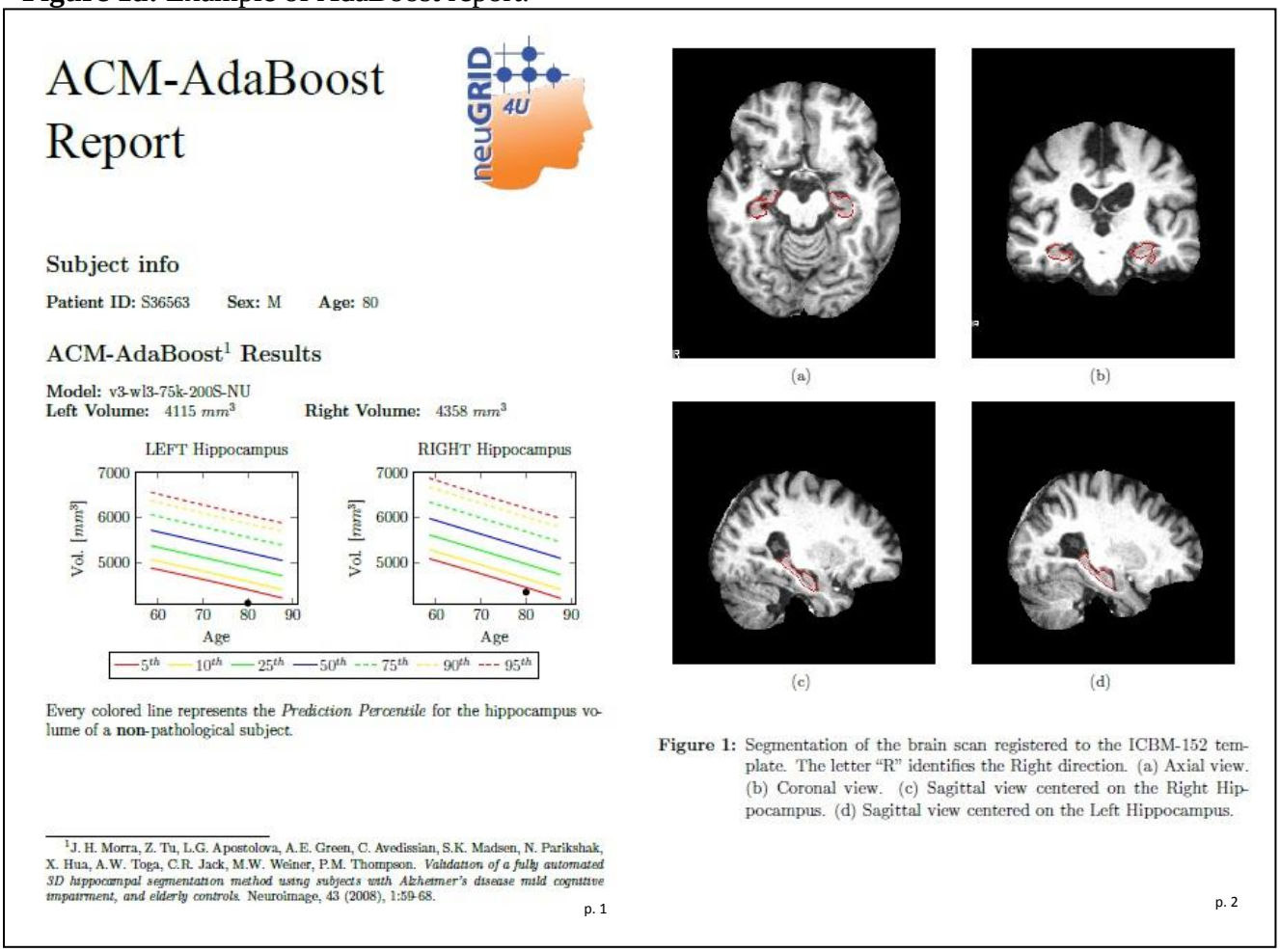

ACM-AdaBoost Report

Subject info

Patient ID: S36563 **Sex:** M **Age:** 80

ACM-AdaBoost[1] Results

Model: v3-wl3-75k-200S-NU
Left Volume: 4115 mm^3 **Right Volume:** 4358 mm^3

Every colored line represents the *Prediction Percentile* for the hippocampus volume of a **non**-pathological subject.

[1] J. H. Morra, Z. Tu, L.G. Apostolova, A.E. Green, C. Avedissian, S.K. Madsen, N. Parikshak, X. Hua, A.W. Toga, C.R. Jack, M.W. Weiner, P.M. Thompson. *Validation of a fully automated 3D hippocampal segmentation method using subjects with Alzheimer's disease mild cognitive impairment, and elderly controls.* Neuroimage, 43 (2008), 1:59-68.

p. 1

Figure 1: Segmentation of the brain scan registered to the ICBM-152 template. The letter "R" identifies the Right direction. (a) Axial view. (b) Coronal view. (c) Sagittal view centered on the Right Hippocampus. (d) Sagittal view centered on the Left Hippocampus.

p. 2

b) FREESURFER

URL: https://neugrid4you.eu/group/science-gateway/freesurfer

How it works: FreeSurfer is an automatic tool labelling hippocampal voxels in an T1-3D MRI volume based on probabilistic information automatically estimated from a manually labeled atlas. Once the MRI is uploaded in neuGRID, Freesurfer provides in 15 hours a .pdf report (fig.1b). The normative dataset is composed by 200 controls. The technique is shown to be comparable in accuracy to manual labeling and of sufficient sensitivity to robustly detect changes in the volumes of hippocampi that presage the onset of probable Alzheimer's disease.
Reference: Fischl et al, Neuron 2002; 33(3):341–55

Figure 1b: Example of Freesurfer output from Neugrid.

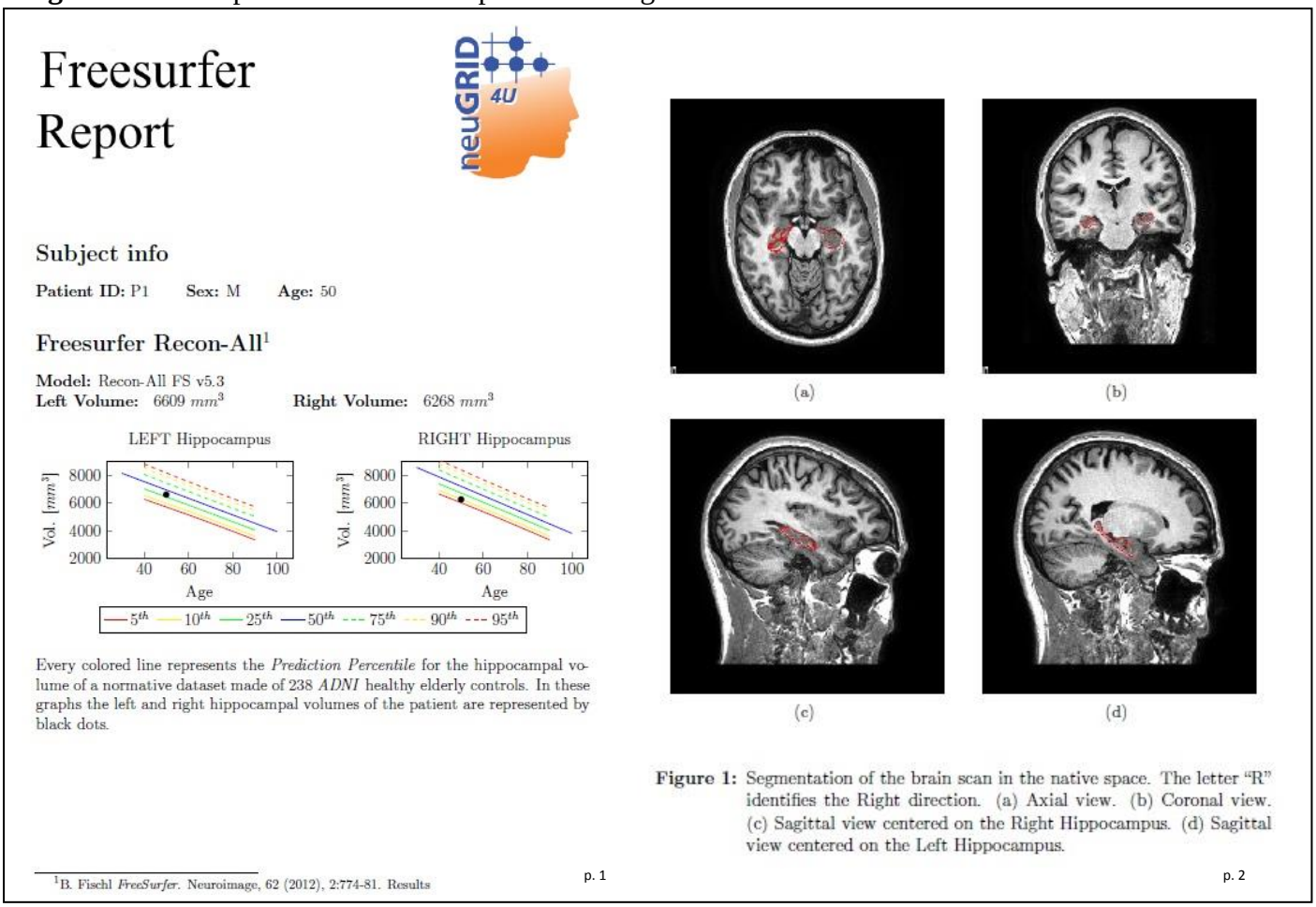

Freesurfer Report

Subject info

Patient ID: P1 **Sex:** M **Age:** 50

Freesurfer Recon-All[1]

Model: Recon-All FS v5.3
Left Volume: 6609 mm^3 **Right Volume:** 6268 mm^3

Every colored line represents the *Prediction Percentile* for the hippocampal volume of a normative dataset made of 238 *ADNI* healthy elderly controls. In these graphs the left and right hippocampal volumes of the patient are represented by black dots.

[1]B. Fischl *FreeSurfer*. Neuroimage, 62 (2012), 2:774-81. Results

Figure 1: Segmentation of the brain scan in the native space. The letter "R" identifies the Right direction. (a) Axial view. (b) Coronal view. (c) Sagittal view centered on the Right Hippocampus. (d) Sagittal view centered on the Left Hippocampus.

c) ASSESSA (LEAP Analysis)

URL: http://assessa.kissdev.co.uk/explore/brain-volumetric-report

How it works: Assessa, a decision support tool developed by IXICO, is based on the Learning Embeddings for Atlas Propagation (LEAP) algorithm and upon a large reference database of images that drive the segmentation of brain regions. It can be used with any 3D T1-weighted MRI scan from 1.5T and 3T scanners. All results are compared to age-matched normal controls in order to give a clear indication of the likelihood of any patient having atrophy that is likely to be due to dementia (Fig. 1c).

LEAP was one of the algorithms included in the EMA qualification of Low Hippocampal Volume as a biomarker to enrich clinical trials of AD in the pre-dementia phase (EMA 2011).

Reference: Wolz et al, Neuroimage 2010;49(2):1316-25.

Figure 1c: Example of LEAP report from Assessa.

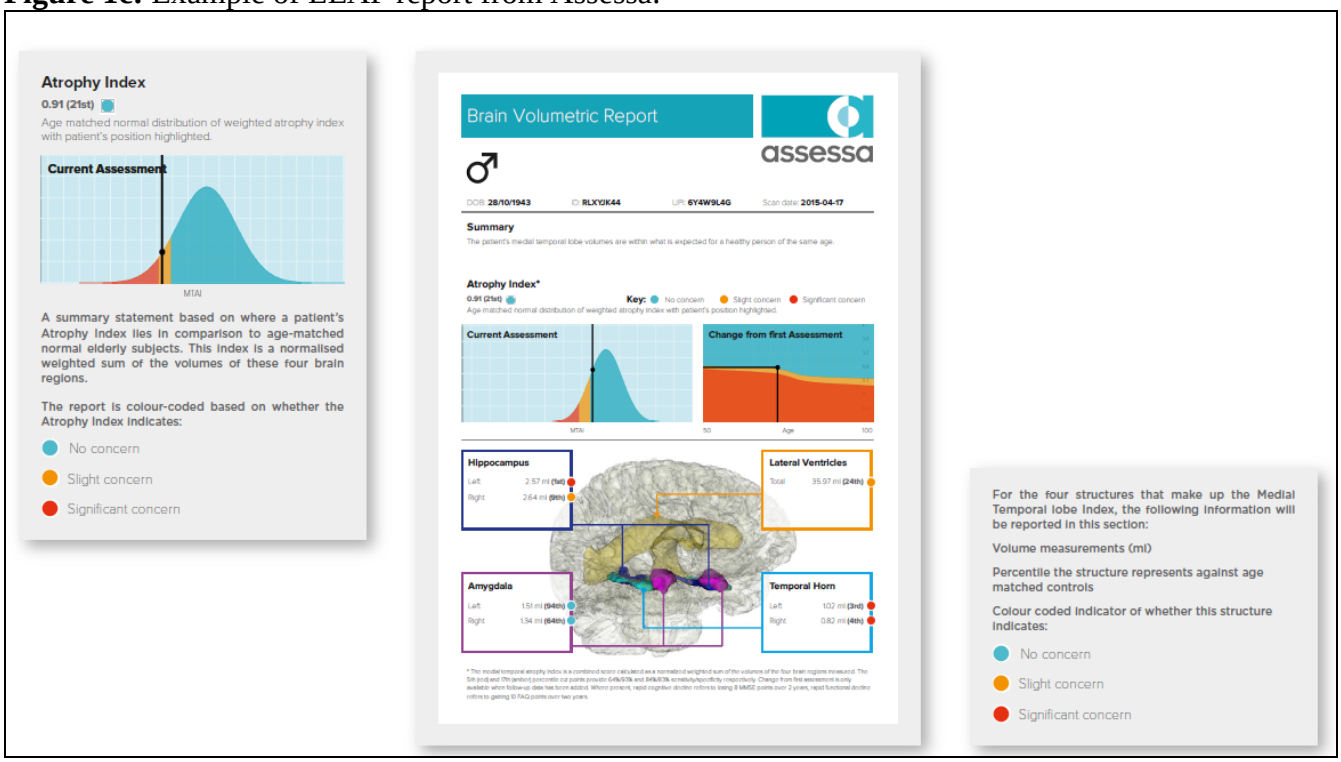

d) NeuroQuant

URL: https://www.cortechslabs.com/neuroquant/

How it works: NeuroQuant is an automatic image segmentation tool from 3D T1 MRI images, developed by CorTechs labs. It provides volumetric measurements of brain structures and compares the volumes to a normative database, adjusted for age, gender and intracranial volume.
The NeuroQuant Age Related Atrophy report (Fig. 1d) contains the absolute and relative volumes of the hippocampus, lateral ventricles, inferior lateral ventricles, and the Hippocampal Occupancy Score (HOC). The resulting values are automatically compared to gender and age-appropriate reference distributions.
It has been the first FDA, CE marked, and Health Canada licensed software for volumetric MRI processing cleared software for volumetric MRI processing.

Figure 1d: Example of NeuroQuant Age Related Atrophy report from CorTechs.

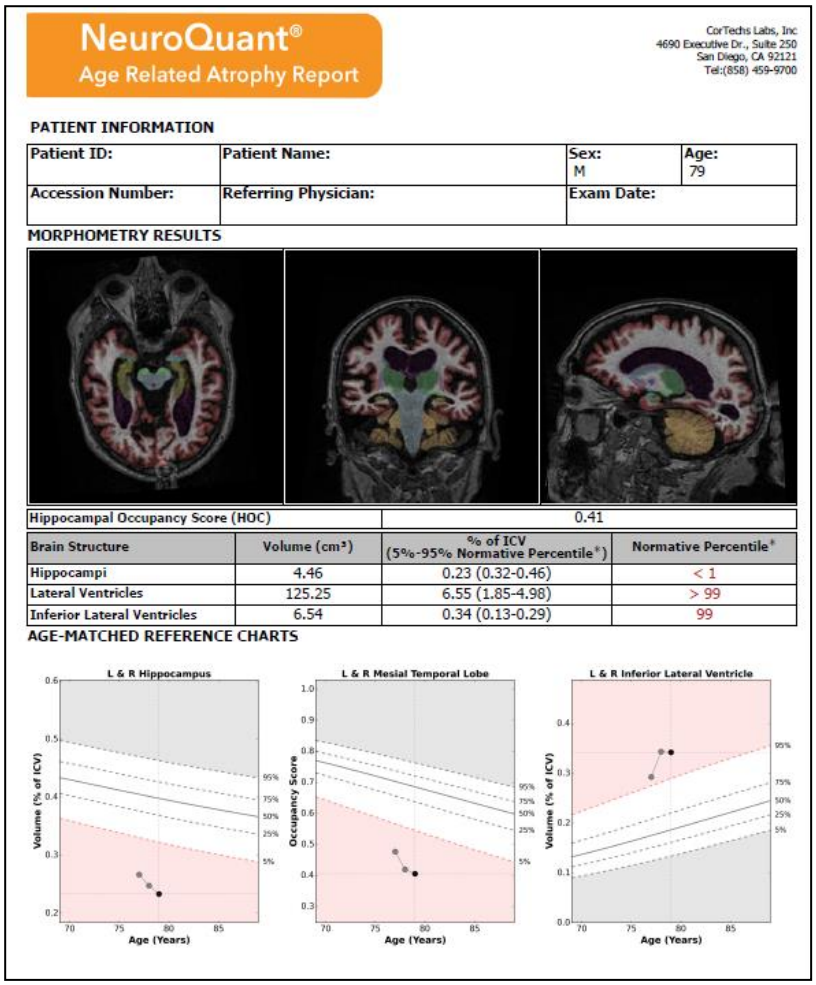

NeuroQuant®
Age Related Atrophy Report

CorTechs Labs, Inc
4690 Executive Dr., Suite 250
San Diego, CA 92121
Tel:(858) 459-9700

PATIENT INFORMATION

Patient ID:	Patient Name:	Sex: M	Age: 79
Accession Number:	Referring Physician:	Exam Date:	

MORPHOMETRY RESULTS

Hippocampal Occupancy Score (HOC)	0.41

Brain Structure	Volume (cm³)	% of ICV (5%-95% Normative Percentile*)	Normative Percentile*
Hippocampi	4.46	0.23 (0.32-0.46)	< 1
Lateral Ventricles	125.25	6.55 (1.85-4.98)	> 99
Inferior Lateral Ventricles	6.54	0.34 (0.13-0.29)	99

AGE-MATCHED REFERENCE CHARTS

e) appMRI Hippocampus Volume Analyser

URL: http://www.neuralyse.eu/en/product

How it works: appMRI Hippocampus Volume Analyser is a fully automated measurement of hippocampal volumes, marked by Mc MRI.
Once a T1-weighted, sagittal, non-contrast enhanced, high resolution 3D MR is uploaded, the tool performs volumetric segmentation using the FreeSurfer image analysis suite and provides a numerical output of left and right hippocampal volume, together with verification images, in a.pdf report (Fig. 1e). In addition, the report contains normative values generated on MRI head scans of an age matched, healthy European control group of people using appMRI Hippocampus Volume Analyser.
The technique results show a linear correlation with the Harmonized Protocol images provided by the EADC-ADNI working Group. The device is intended to be used by trained professionals.
appMRI Hippocampus Volume Analyser is a certified medical device according to the European Medical Device Directive.

Figure 1e: Example of appMRI Hippocampus Volume Analyser report.

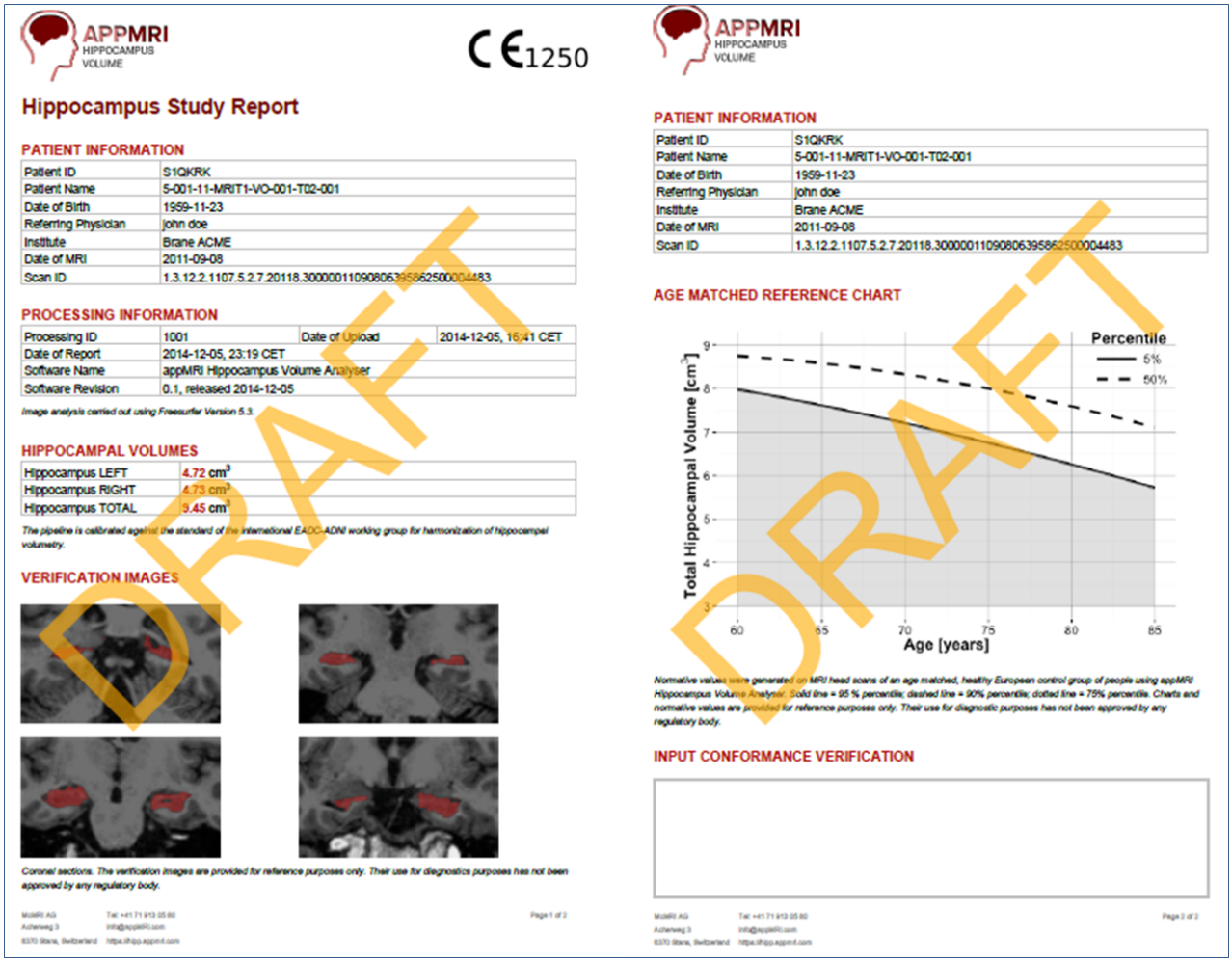

APPMRI HIPPOCAMPUS VOLUME

CE 1250

Hippocampus Study Report

PATIENT INFORMATION

Patient ID	S1QKRK
Patient Name	5-001-11-MRIT1-VO-001-T02-001
Date of Birth	1959-11-23
Referring Physician	john doe
Institute	Brane ACME
Date of MRI	2011-09-08
Scan ID	1.3.12.2.1107.5.2.7.20118.30000011090806395862500004483

PROCESSING INFORMATION

Processing ID	1001	Date of Upload	2014-12-05, 16:41 CET
Date of Report	2014-12-05, 23:19 CET		
Software Name	appMRI Hippocampus Volume Analyser		
Software Revision	0.1, released 2014-12-05		

Image analysis carried out using Freesurfer Version 5.3.

HIPPOCAMPAL VOLUMES

Hippocampus LEFT	4.72 cm^3
Hippocampus RIGHT	4.73 cm^3
Hippocampus TOTAL	9.45 cm^3

The pipeline is calibrated against the standard of the international EADC-ADNI working group for harmonization of hippocampal volumetry.

VERIFICATION IMAGES

Coronal sections. The verification images are provided for reference purposes only. Their use for diagnostics purposes has not been approved by any regulatory body.

Page 1 of 2

APPMRI HIPPOCAMPUS VOLUME

PATIENT INFORMATION

Patient ID	S1QKRK
Patient Name	5-001-11-MRIT1-VO-001-T02-001
Date of Birth	1959-11-23
Referring Physician	john doe
Institute	Brane ACME
Date of MRI	2011-09-08
Scan ID	1.3.12.2.1107.5.2.7.20118.30000011090806395862500004483

AGE MATCHED REFERENCE CHART

Normative values were generated on MRI head scans of an age matched, healthy European control group of people using appMRI Hippocampus Volume Analyser. Solid line = 95 % percentile; dashed line = 90% percentile; dotted line = 75% percentile. Charts and normative values are provided for reference purposes only. Their use for diagnostic purposes has not been approved by any regulatory body.

INPUT CONFORMANCE VERIFICATION

Page 2 of 2

f) ARDX®

URL: http://www.jung-diagnostics.de/eng/ardx_eng.php

How it works: Risk assessment of Alzheimer's disease (ARDX) is a fully-automated tool for quantification of hippocampal volumetry, based on an atlas-based pipeline, created using Statistical Parametric Mapping (SPM) software, marked by Jung Diagnostics (JDX).
Jung JDX's experts perform a quality control check on the high-resolution 3D T1-weighted gradient echo sequence images sent and, after the automated hippocampus quantification and a second expert visual quality control, a report is sent to clinician (report available only in German. Fig 1f).
ARDX® is a certified medical device (with CE mark) commercially available.

Reference: Suppa et al, J Alzheimers 2015 Dis 44:183–193.

Figure 1f: Example of ARDX report.

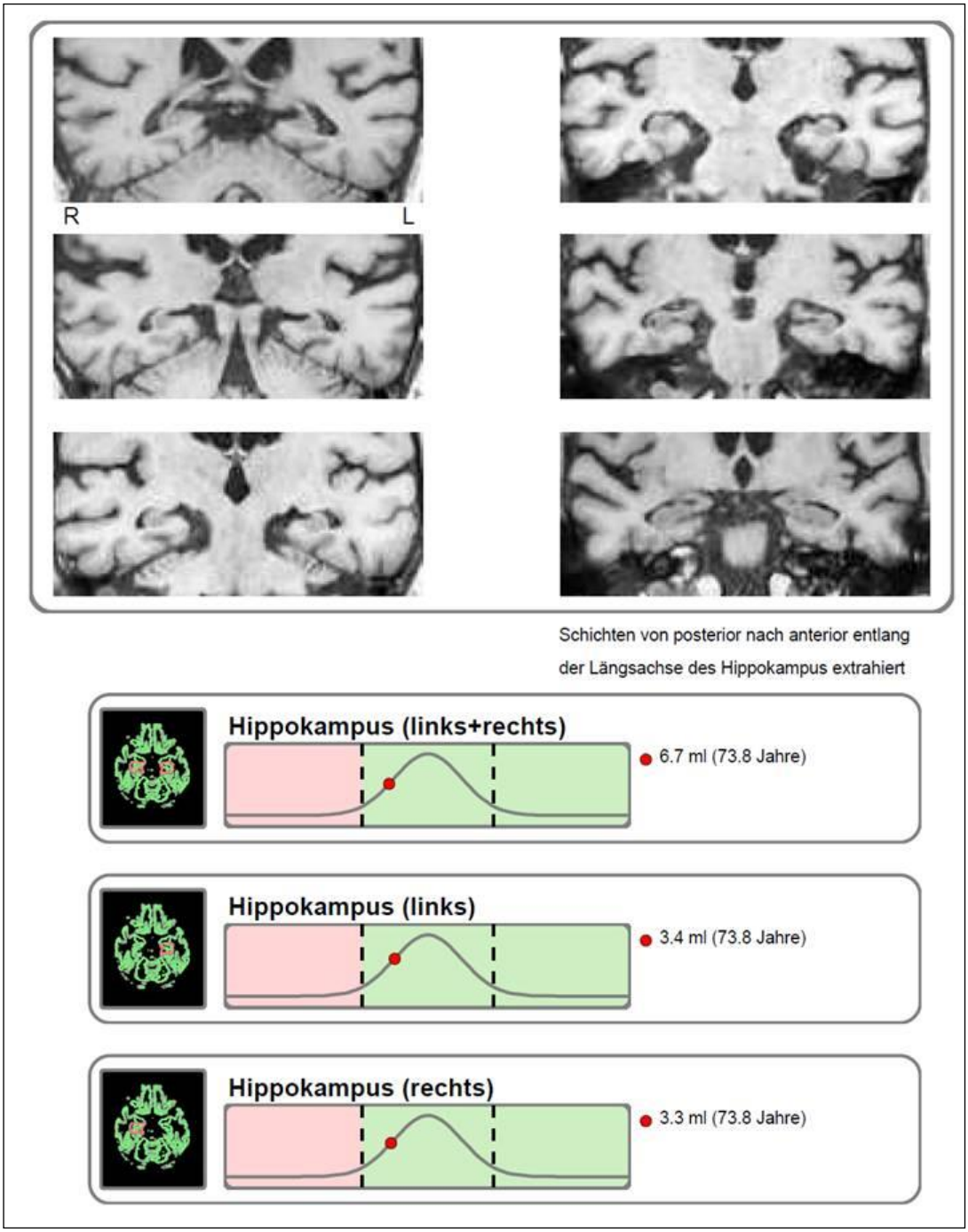

g) Quantib Brain

URL: http://www.quantib.com/software/

How it works: Quantib is a white matter hyperintensity and brain tissue quantification's tool, fully integrated with the GE Advantage Workstation workflow. It can perform longitudinal analysis, comparing multiple exams of the same patient. Its clinically-validated algorithms have been tested on over 10,000 scans in the Rotterdam Scan Study dataset. Quantib products are ISO-13485:2012 certified and FDA cleared.

Quantib provides services in a wide range of quantitative analysis problems in the neuro domain, such as quantification of brain tissue, CSF and brain lobe volumes, segmentation of neurostructures and shape analysis of neurostructures.

Reference: Vrooman HA et al., Neuroimage. 2007;37(1):71-81

Figure 1g: Example of Quantib Brain report.

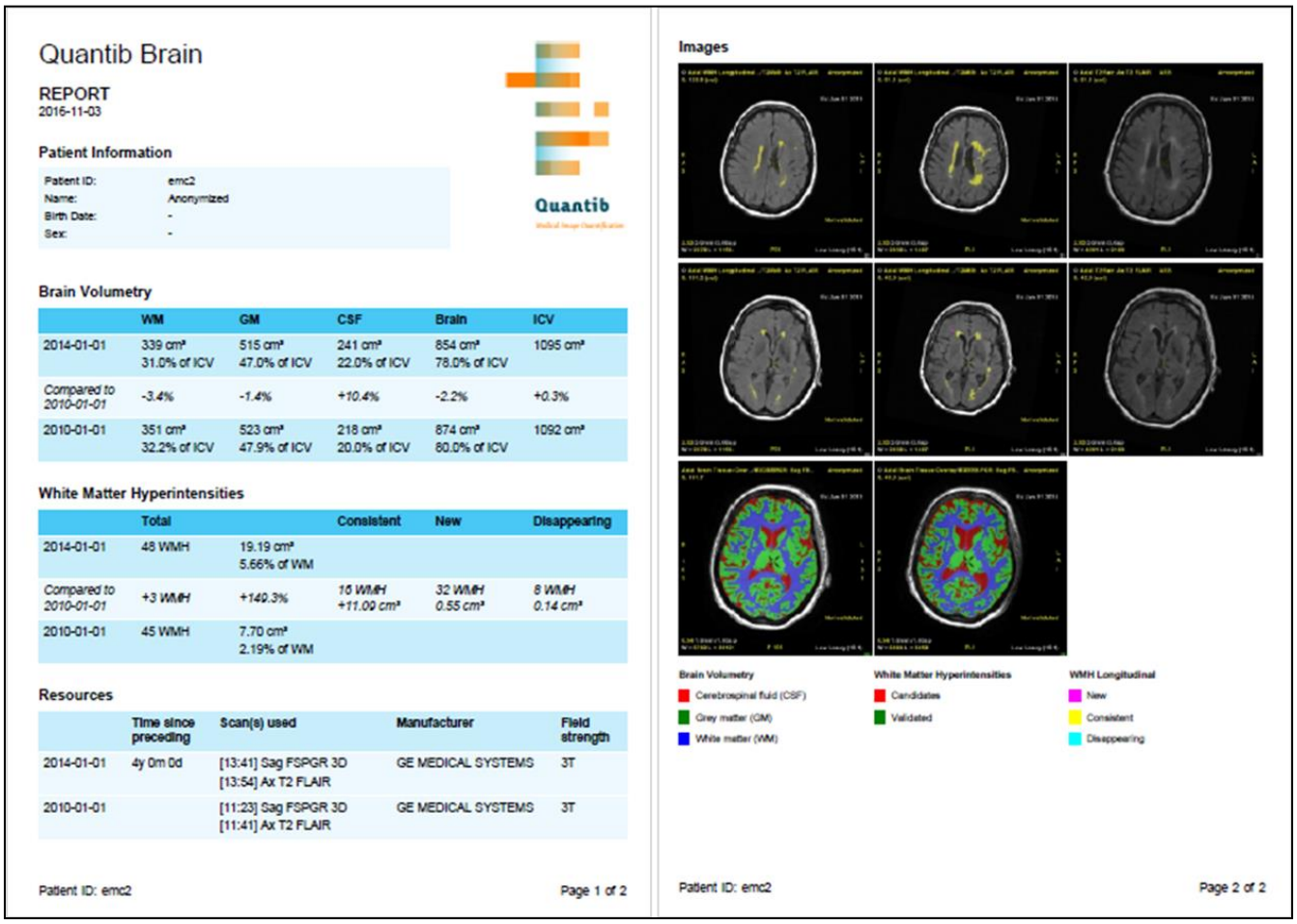

Quantib Brain

REPORT
2016-11-03

Patient Information

Patient ID:	emc2
Name:	Anonymized
Birth Date:	-
Sex:	-

Brain Volumetry

	WM	GM	CSF	Brain	ICV
2014-01-01	339 cm³ 31.0% of ICV	515 cm³ 47.0% of ICV	241 cm³ 22.0% of ICV	854 cm³ 78.0% of ICV	1095 cm³
Compared to 2010-01-01	*-3.4%*	*-1.4%*	*+10.4%*	*-2.2%*	*+0.3%*
2010-01-01	351 cm³ 32.2% of ICV	523 cm³ 47.9% of ICV	218 cm³ 20.0% of ICV	874 cm³ 80.0% of ICV	1092 cm³

White Matter Hyperintensities

	Total		Consistent	New	Disappearing
2014-01-01	48 WMH	19.19 cm³ 5.66% of WM			
Compared to 2010-01-01	*+3 WMH*	*+149.3%*	*16 WMH* *+11.09 cm³*	*32 WMH* *0.55 cm³*	*8 WMH* *0.14 cm³*
2010-01-01	45 WMH	7.70 cm³ 2.19% of WM			

Resources

	Time since preceding	Scan(s) used	Manufacturer	Field strength
2014-01-01	4y 0m 0d	[13:41] Sag FSPGR 3D [13:54] Ax T2 FLAIR	GE MEDICAL SYSTEMS	3T
2010-01-01		[11:23] Sag FSPGR 3D [11:41] Ax T2 FLAIR	GE MEDICAL SYSTEMS	3T

Patient ID: emc2 Page 1 of 2

Images

Brain Volumetry
- Cerebrospinal fluid (CSF)
- Grey matter (GM)
- White matter (WM)

White Matter Hyperintensities
- Candidates
- Validated

WMH Longitudinal
- New
- Consistent
- Disappearing

Patient ID: emc2 Page 2 of 2

h) volMETRIX

URL: http://truepositivemd.com/product-tour/

How it works: volMETRIX is a fully automatic segmentation tool developed and marked by True Positive Medical Devices Inc. Once a standardized, T1-weighted MRI is uploaded, volMETRIX automatically processes the data, applies expert visual quality control, and sends a customizable report (report not available). It can compute either cross sectional or longitudinal MRI data from 1.0T to 3.0T acquired T1-weighted images.

Reference: Collins et al, NeuroImage 2010;52(4):1355-66.

i) MorphoBox

URL:http://w1.siemens.ch/home/ch/de/healthcare/produkte/ACIT/Projects/Pages/Tissueclassification.aspx

How it works: MorphoBox is a work-in-progress project, belonging to a Siemens brain morphometry package (WIP542) which aims to automatically compute brain atrophy measurements at scan time to assist clinicians in the diagnosis and prognosis of brain diseases.
MorphoBox is an algorithm for tissue segmentation of T1-weighted images (e.g. MPRAGE) MRI images useful for quantification of brain atrophy patterns. It uses a statistical inference approach based on Markov random field image models to reflect both unbiased prior anatomical knowledge and image characteristics such as RF inhomogeneity and partial volume effects.
Report not provided.

Reference: Collins et al., NeuroImage 2010;52(4):1355-66.

j) MSmetrix (quantitative MRI biomarkers'tool for Multiple Sclerosis)

URL: https://icometrix.com/#!/en/services/

How it works: MSmetrix is a CE marked brain MRI tool developed by icometrix. It is an automatic method for lesion segmentation based on 3D T1-weighted MRI images, independent of scanner or acquisition protocol or field strengths (1.5T, 3T and 7T) and without requiring any training data.
The images are preprocessed and co-registered before executing the main loop of the algorithm, consisting of brain tissue segmentation, lesion segmentation and lesion filling. Once scans have been processed, a .pdf report (fig. 1j), describing the whole brain volume and the grey matter volume, will be generated and sent by email.

Reference: Jain et al., Neuroimage Clin. 2015;16;8:367-75.

Figure 1j: Example of MSmetrix report.

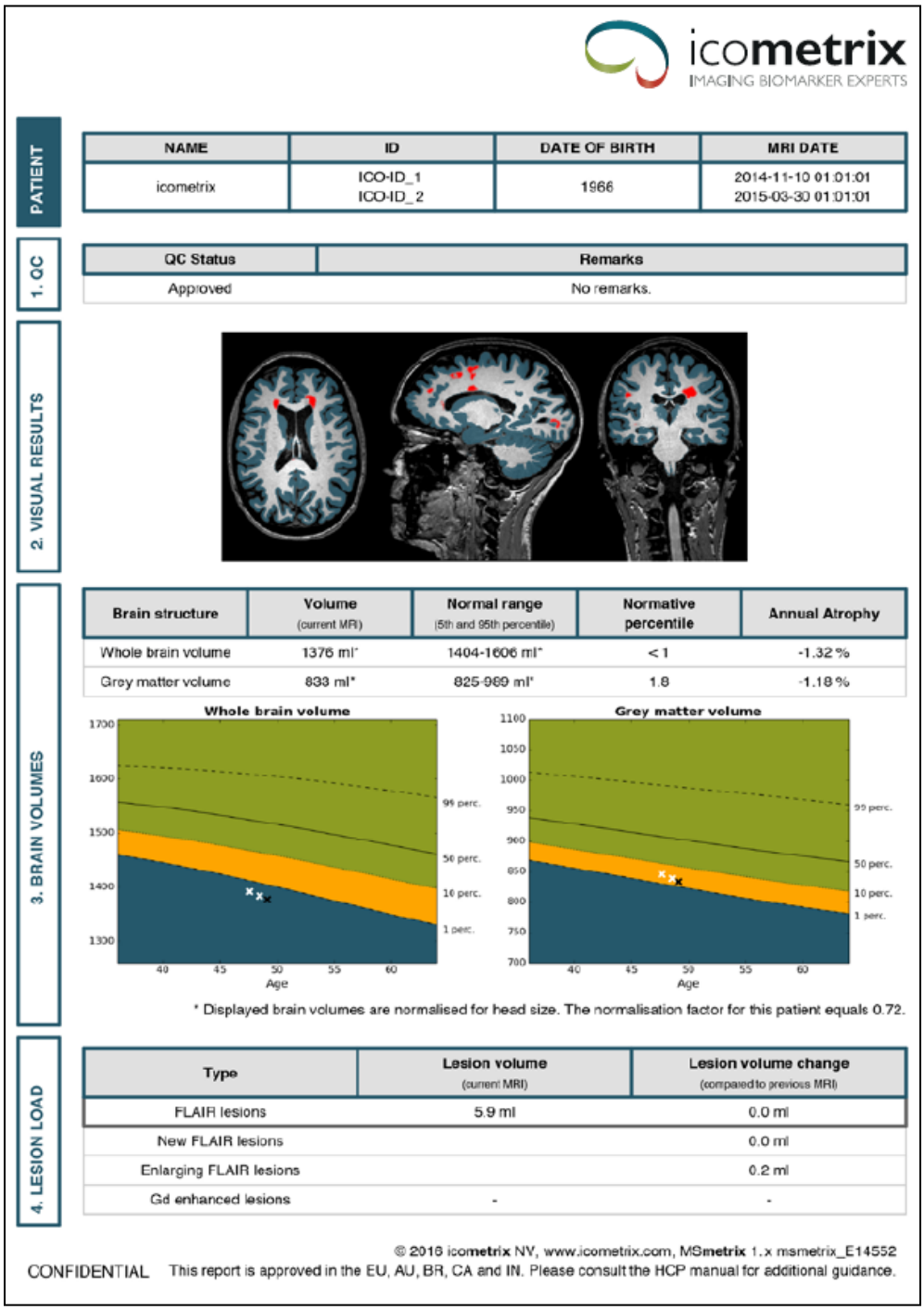

icometrix
IMAGING BIOMARKER EXPERTS

PATIENT

NAME	ID	DATE OF BIRTH	MRI DATE
icometrix	ICO-ID_1 ICO-ID_2	1966	2014-11-10 01:01:01 2015-03-30 01:01:01

1. QC

QC Status	Remarks
Approved	No remarks.

2. VISUAL RESULTS

3. BRAIN VOLUMES

Brain structure	Volume (current MRI)	Normal range (5th and 95th percentile)	Normative percentile	Annual Atrophy
Whole brain volume	1376 ml*	1404-1606 ml*	< 1	-1.32 %
Grey matter volume	833 ml*	825-969 ml*	1.8	-1.18 %

* Displayed brain volumes are normalised for head size. The normalisation factor for this patient equals 0.72.

4. LESION LOAD

Type	Lesion volume (current MRI)	Lesion volume change (compared to previous MRI)
FLAIR lesions	5.9 ml	0.0 ml
New FLAIR lesions		0.0 ml
Enlarging FLAIR lesions		0.2 ml
Gd enhanced lesions	-	-

CONFIDENTIAL This report is approved in the EU, AU, BR, CA and IN. Please consult the HCP manual for additional guidance.

ASSESSMENT OF WHITE MATTER HYPERINTENSITIES

a) ASSESSA (Vascular Report)

URL: http://assessa.kissdev.co.uk/explore/vascular-report

How it works: The Assessa Vascular Report, a decision support tool developed by IXICO, provides automated quantification of the percentage of White Matter Hyperintensities (WMH) volume within total white matter and for a number of brain regions (including juxtaventricular, periventricular, deep, and juxtacortical), using MRI T1W and FLAIR images. The tool is based on an in-house implementation of the Lesion Segmentation Tool (LST, created by SPM), so that the final segmentation is obtained by iteratively updating all five models (CSF, GM, WM, WMH, non-WMH) simultaneously.
For each region, the Assessa Vascular Report (Fig.2a) colour-codes the display dependent on cut-points that have been derived from the percentage of WMH in total WM.

Reference: Joules et al., Alzheimer's & Dementia 2016, 12; (4), P63.

Fig. 2a: Example of a Vascular Report from Assessa

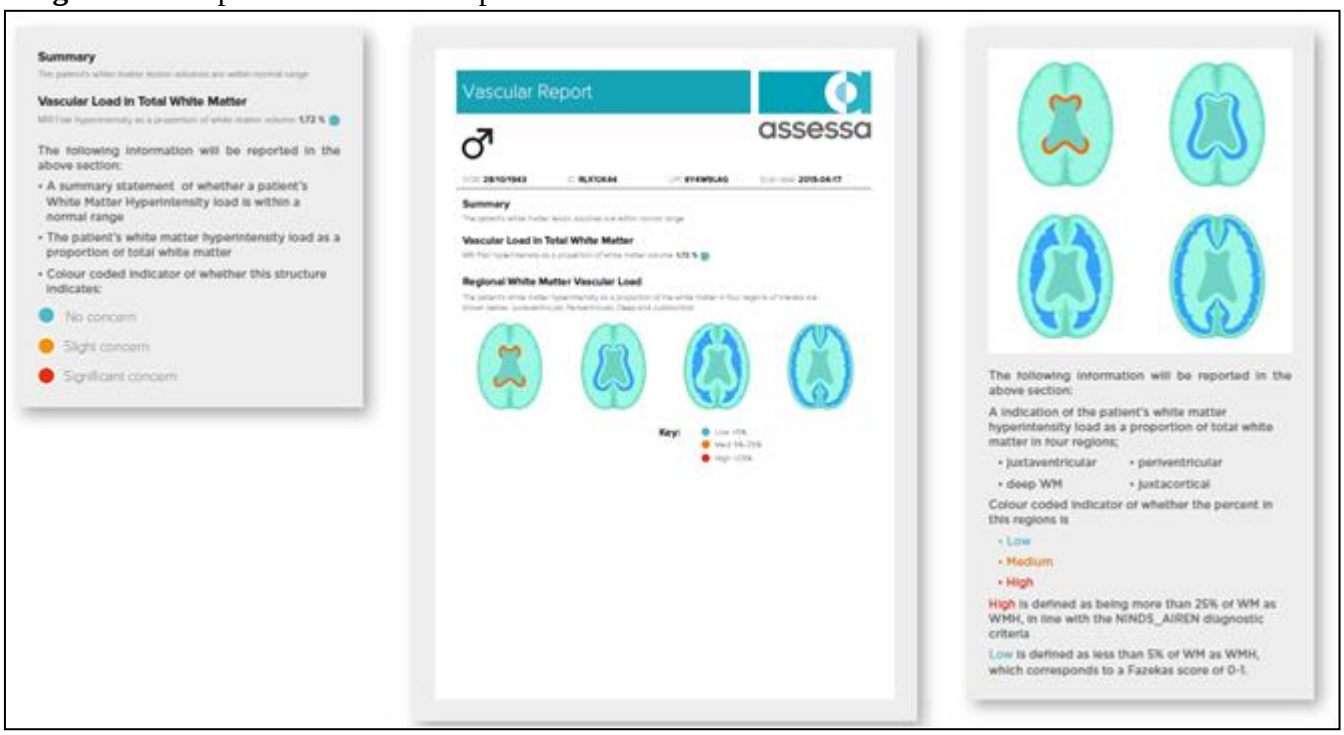

b) LesionQuant

URL: https://www.cortechslabs.com/lesionquant/

How it works: LesionQuant is a thorough automated white matter lesion segmentation and quantification tool, developed and marked by CorTechs labs. By combining FLAIR and 3D T1 image analysis, it automatically segments and measures volumes of brain structures, compares these volumes to norms and defines lesions as areas of increased FLAIR MRI signal intensity above a set threshold when compared to the surrounding tissue (areas greater than or equal to 4 voxels will be considered a lesion). It provides an FLAIR lesion and brain structure volumetric report (fig. 2b) and allows to visualize lesions and lesion change.

Figure 2b: Example of LesionQuant FLAIR Lesion report from CorTechs.

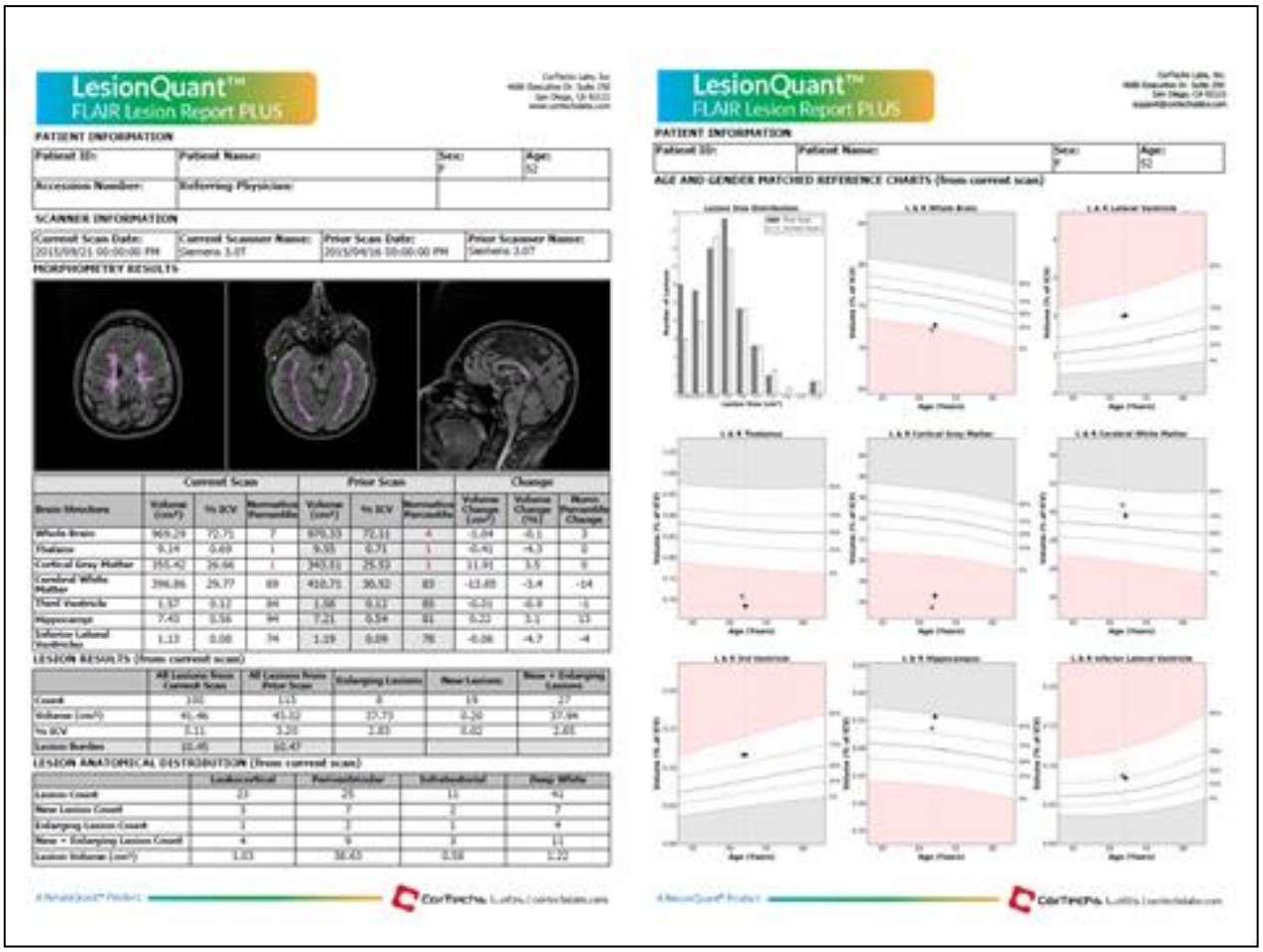

c) Quantib Brain

URL: http://www.quantib.com/software/

How it works: Quantib is a white matter hyperintensity and brain tissue quantification's tool, fully integrated with the GE Advantage Workstation workflow. It can perform longitudinal analysis, comparing multiple exams of the same patient. Its clinically-validated algorithms have been tested on over 10,000 scans in the Rotterdam Scan Study dataset. Quantib products are ISO-13485:2012 certified and FDA cleared.

Reference: de Boer R et al., Neuroimage. 2009;45(4):1151-61

Figure 2c: Example of Quantib Brain report.

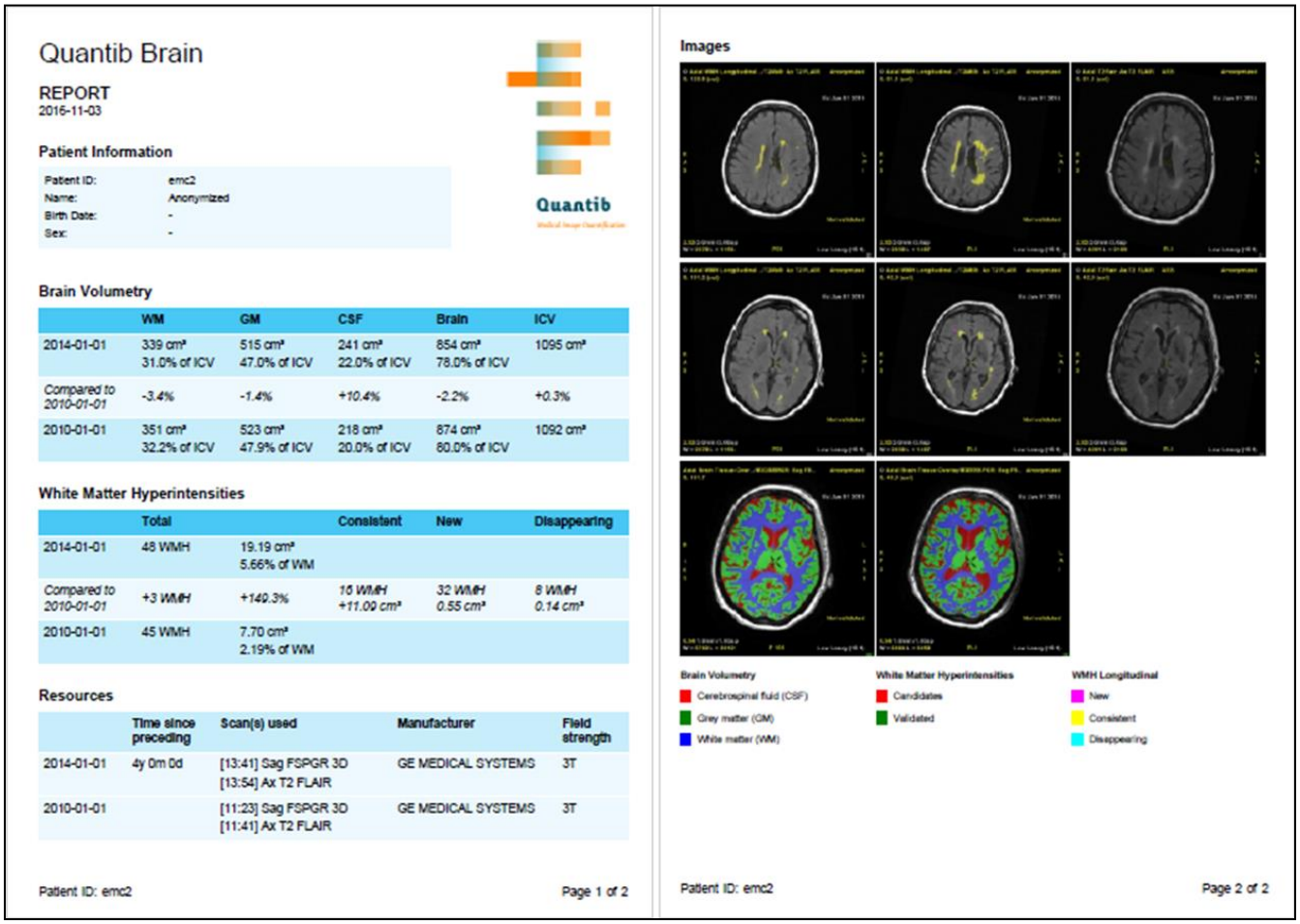

Quantib Brain

REPORT
2016-11-03

Patient Information

Patient ID:	emc2
Name:	Anonymized
Birth Date:	-
Sex:	-

Brain Volumetry

	WM	GM	CSF	Brain	ICV
2014-01-01	339 cm³ 31.0% of ICV	515 cm³ 47.0% of ICV	241 cm³ 22.0% of ICV	854 cm³ 78.0% of ICV	1095 cm³
Compared to 2010-01-01	*-3.4%*	*-1.4%*	*+10.4%*	*-2.2%*	*+0.3%*
2010-01-01	351 cm³ 32.2% of ICV	523 cm³ 47.9% of ICV	218 cm³ 20.0% of ICV	874 cm³ 80.0% of ICV	1092 cm³

White Matter Hyperintensities

	Total		Consistent	New	Disappearing
2014-01-01	48 WMH	19.19 cm³ 5.66% of WM			
Compared to 2010-01-01	*+3 WMH*	*+149.3%*	*16 WMH* *+11.09 cm³*	*32 WMH* *0.55 cm³*	*8 WMH* *0.14 cm³*
2010-01-01	45 WMH	7.70 cm³ 2.19% of WM			

Resources

	Time since preceding	Scan(s) used	Manufacturer	Field strength
2014-01-01	4y 0m 0d	[13:41] Sag FSPGR 3D [13:54] Ax T2 FLAIR	GE MEDICAL SYSTEMS	3T
2010-01-01		[11:23] Sag FSPGR 3D [11:41] Ax T2 FLAIR	GE MEDICAL SYSTEMS	3T

Patient ID: emc2 Page 1 of 2

Images

Brain Volumetry
- Cerebrospinal fluid (CSF)
- Grey matter (GM)
- White matter (WM)

White Matter Hyperintensities
- Candidates
- Validated

WMH Longitudinal
- New
- Consistent
- Disappearing

Patient ID: emc2 Page 2 of 2

d) MSmetrix (quantitative MRI biomarkers' tool for Multiple Sclerosis)

URL: https://icometrix.com/#!/en/services/

How it works: MSmetrix is a CE marked brain MRI tool developed by Icometrix. It works with any type of scanner or acquisition protocol or field strengths (1.5T, 3T and 7T) and without requiring any training data. In MSmetrix, 3D T1-weighted and FLAIR MR images are used in a probabilistic model to detect white matter (WM) lesions as an outlier to normal brain while segmenting the brain tissue into grey matter,WM and cerebrospinal fluid. The actual lesion segmentation is performed based on prior knowledge about the location (within WM) and the appearance (hyperintense on FLAIR) of lesions.
The images are preprocessed and co-registered before executing the main loop of the algorithm, consisting of brain tissue segmentation, lesion segmentation and lesion filling. Once scans have been processed, a .pdf report (fig. 2c) will be generated and sent by email.

Reference: Jain et al., Neuroimage Clin. 2015;16;8:367-75.

Figure 2d: Example of MSmetrix report.

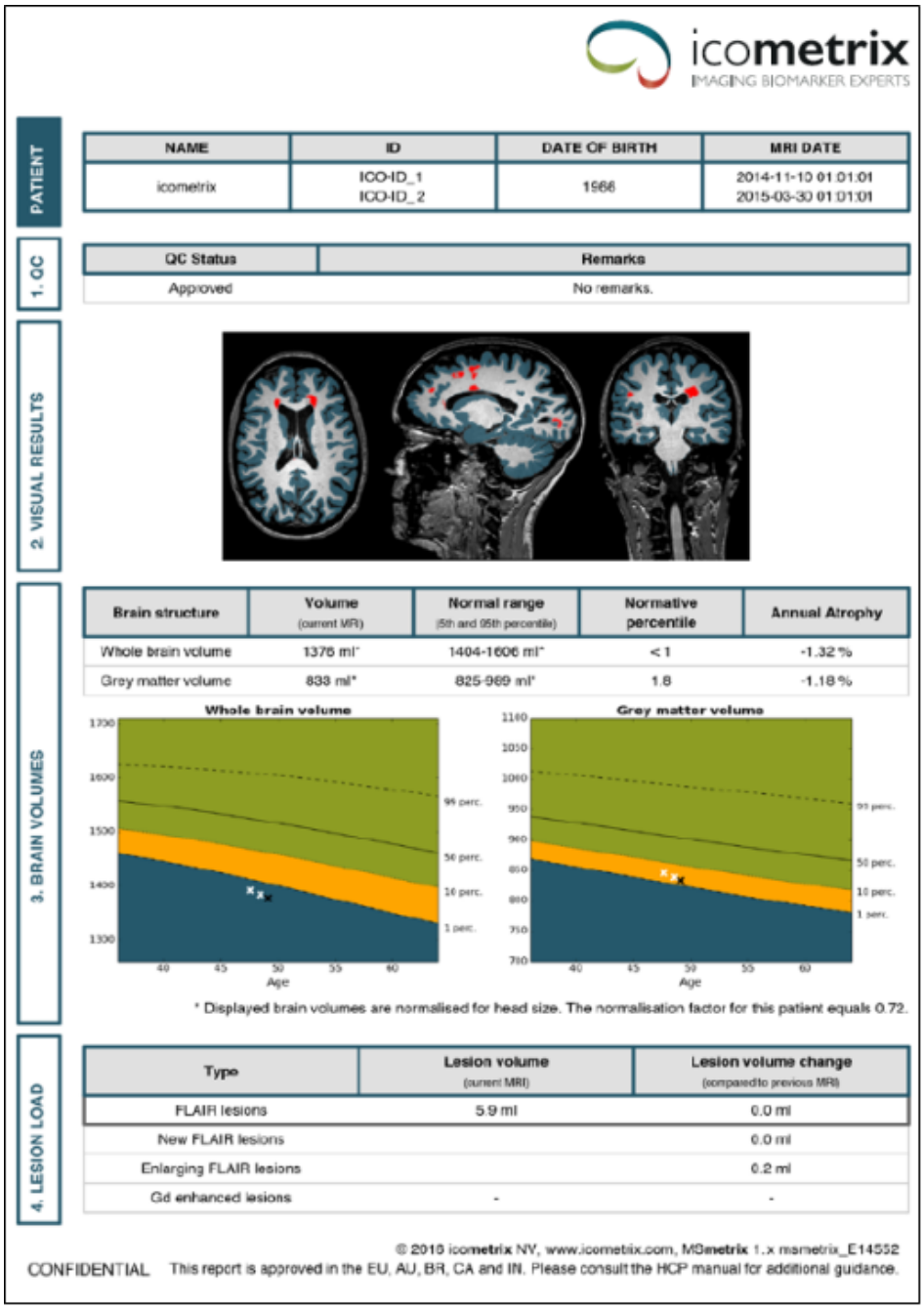

icometrix
IMAGING BIOMARKER EXPERTS

PATIENT

NAME	ID	DATE OF BIRTH	MRI DATE
icometrix	ICO-ID_1 ICO-ID_2	1966	2014-11-10 01:01:01 2015-03-30 01:01:01

1. QC

QC Status	Remarks
Approved	No remarks.

2. VISUAL RESULTS

3. BRAIN VOLUMES

Brain structure	Volume (current MRI)	Normal range (5th and 95th percentile)	Normative percentile	Annual Atrophy
Whole brain volume	1376 ml*	1404-1606 ml*	< 1	-1.32 %
Grey matter volume	833 ml*	825-969 ml*	1.8	-1.18 %

* Displayed brain volumes are normalised for head size. The normalisation factor for this patient equals 0.72.

4. LESION LOAD

Type	Lesion volume (current MRI)	Lesion volume change (compared to previous MRI)
FLAIR lesions	5.9 ml	0.0 ml
New FLAIR lesions		0.0 ml
Enlarging FLAIR lesions		0.2 ml
Gd enhanced lesions	-	-